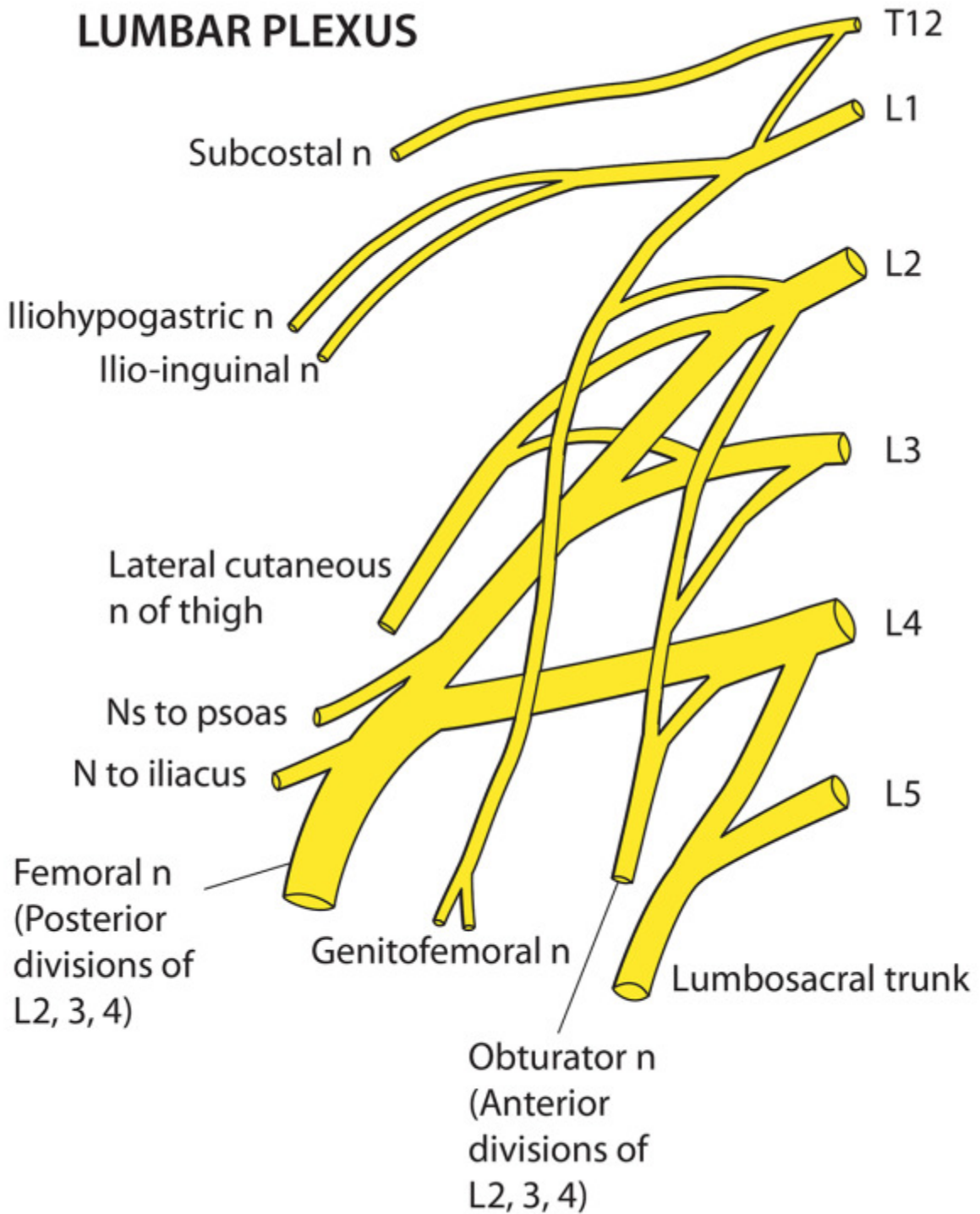
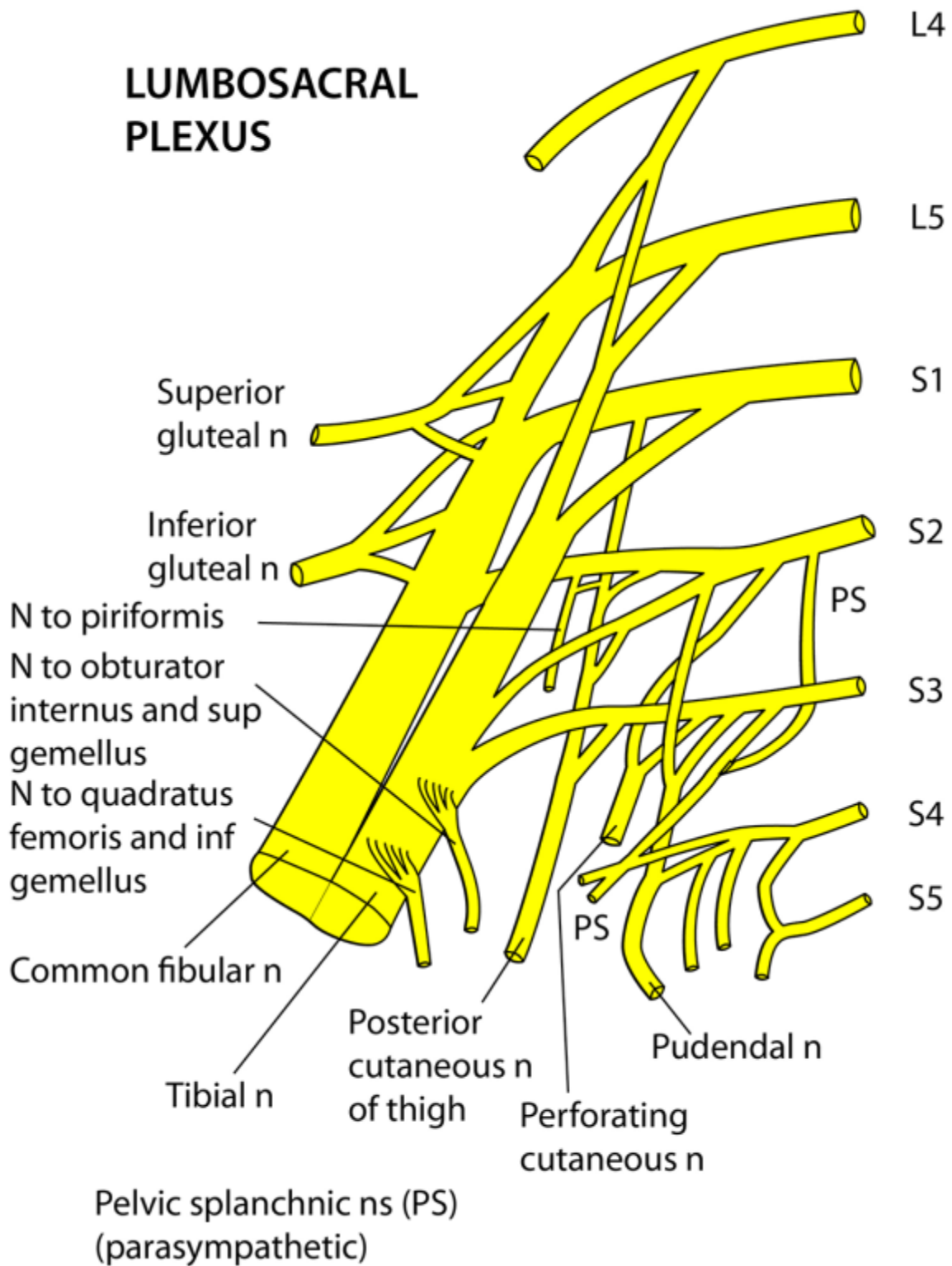


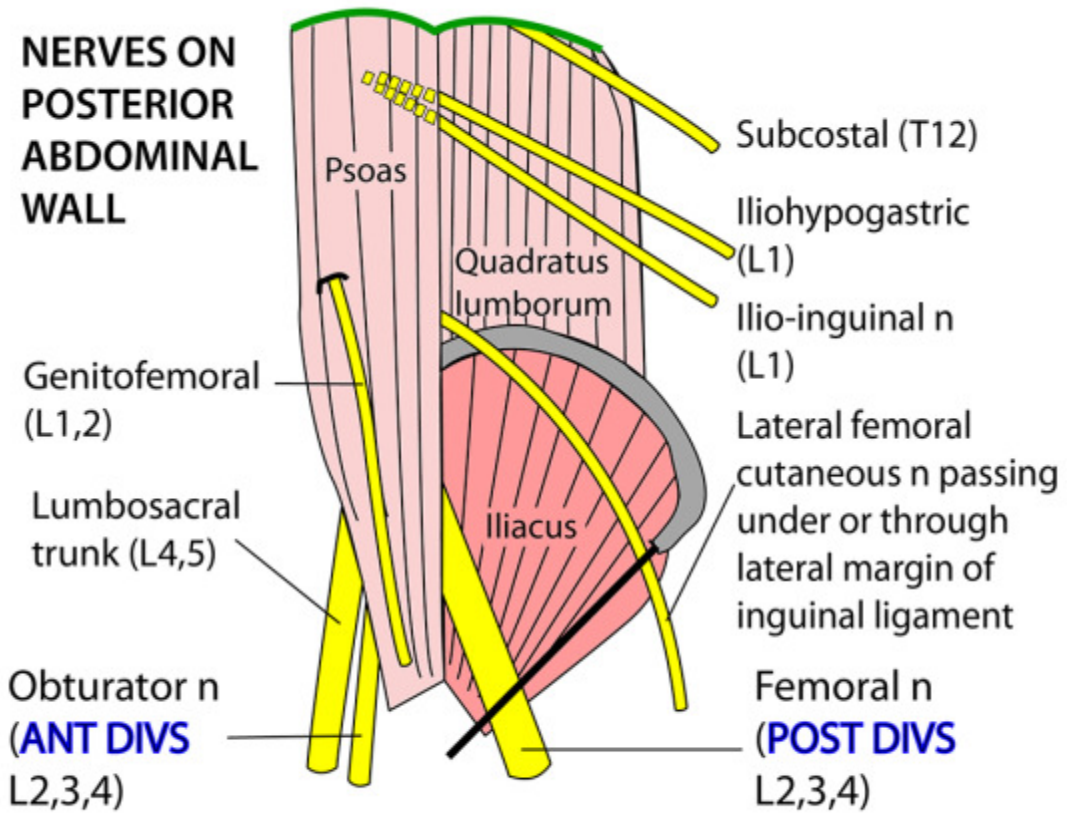
Posterior abdominal wall nerves



LUMBOSACRAL PLEXUS



NERVES ON POSTERIOR ABDOMINAL WALL



NERVES IN PSOAS

