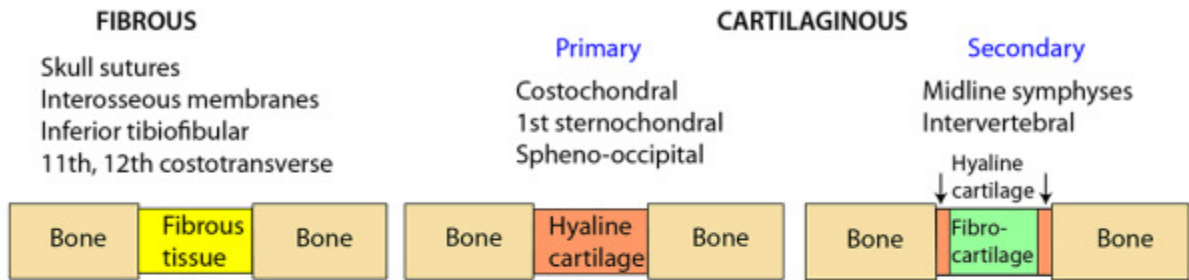
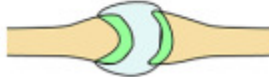

CLASSIFICATION OF JOINTS



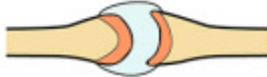ATYPICAL SYNOVIAL

Articular surface covered with fibrocartilage
 Tempormandibular
 Sternoclavicular
 Acromioclavicular
 2-7 Sternochondral



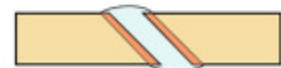TYPICAL SYNOVIAL

Articular surface covered with hyaline cartilage
 All other synovial joints



MOVEMENTS IN SYNOVIAL JOINTS

- PLANE Gliding
Tarsus & carpus



● HINGE

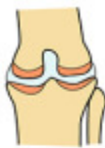Interphalangeal



Flexion
Extension

● MODIFIED HINGE

Knee



Flexion
Extension
Rotation with flexed knee

● CONDYLOID

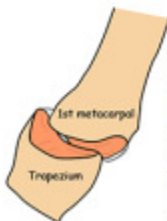Metacarpophalangeal



Flexion
Extension
Adduction
Abduction
Circumduction

● SADDLE CONDYLOID

1st Carpometacarpal

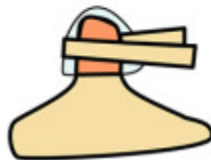


Flexion
Extension
Adduction
Abduction
Circumduction
"Controlled" rotation = opposition

● PIVOT

Both ends of radius
Atlanto-axial

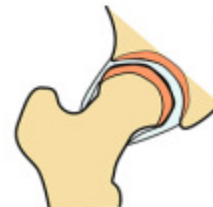Rotation
(Uni-axial)



nerves

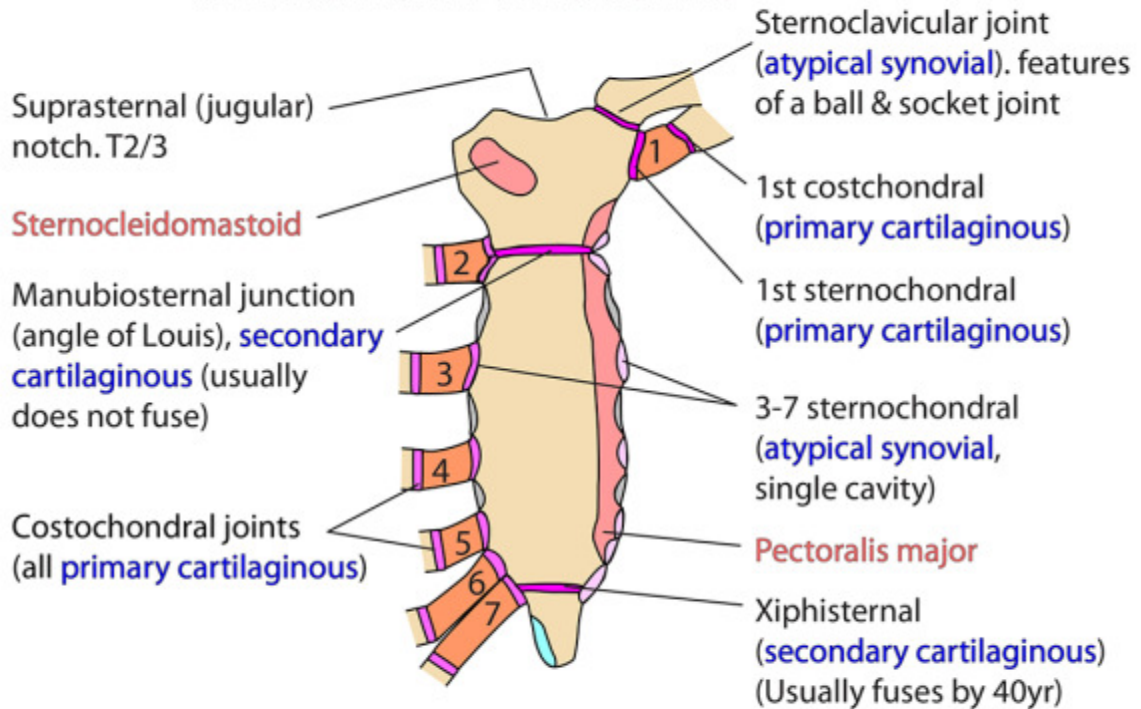
● BALL AND SOCKET

Hip
Shoulder
(Sternoclavicular
Talocalcaneonavicular - many features of one)



Flexion
Extension
Adduction
Abduction
Circumduction
"Free" rotation

STERNUM & RELATED JOINTS



TYPICAL INTERCOSTAL NERVE

