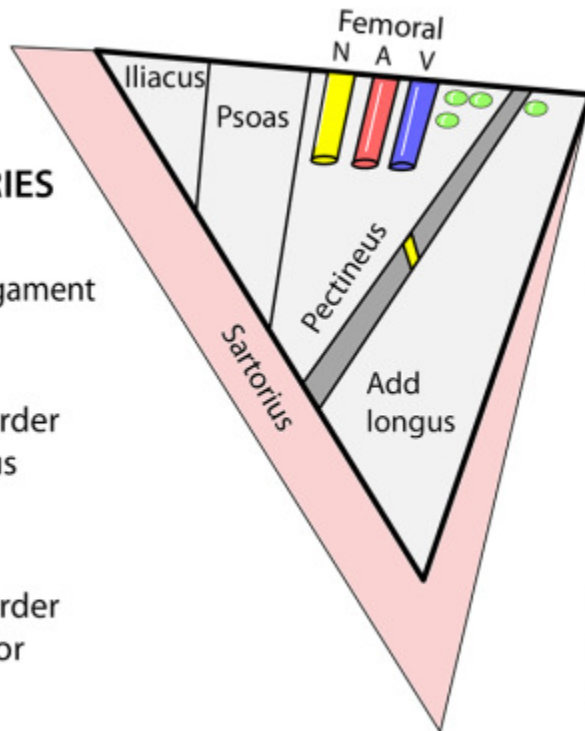


Femoral Triangle and Femoral Canal

FEMORAL TRIANGLE

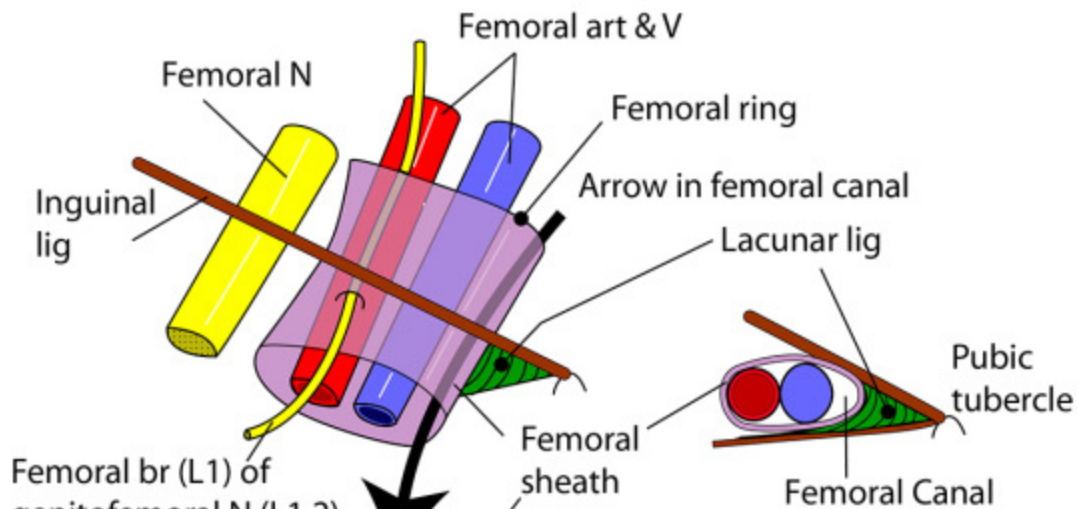
BOUNDARIES

- Superior:**
- Inguinal ligament
- Lateral:**
- Medial border of sartorius
- Medial:**
- Medial border of adductor longus



- Roof:**
- Fascia lata
- Floor:**
- Muscles as shown with adductor brevis just showing. It has the anterior division of the obturator nerve on its surface
- Contains:**
- Femoral nerve
 - Femoral artery
 - Femoral vein
 - Deep inguinal nodes

RIGHT FEMORAL CANAL, SHEATH & RING



Femoral br (L1) of genitofemoral N (L1,2) supplying skin over femoral triangle

Excludes femoral n. Ant. layer from transversalis fascia & post. layer from fascia over psoas

Borders - ant: inguinal ligament, **med:** lacunar ligament, **post:** pectineal ligament & pectineus, **lat:** femoral vein
Contains: Lymphatics from lower limb & Cloquet's lymph node