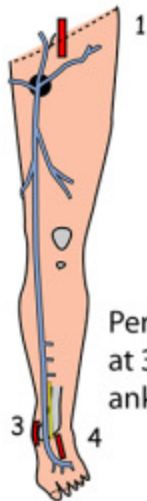


VEINS AND PULSES IN THE LOWER LIMB

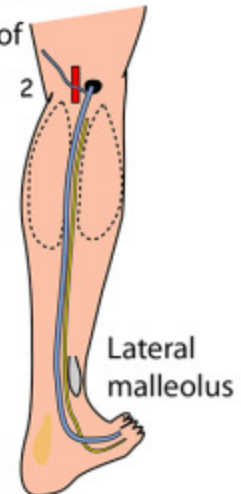


Anterior view of left lower limb to show:
GREAT (LONG) SAPHENOUS VEIN

Perforating veins at 3,6,9cm above ankle

Great saphenous vein commences at the medial side of the dorsal venous arch and passes just anterior to the medial malleolus with the saphenous vein lying alongside it. It passes a hand's breadth posteromedial to the patella

Posterolateral view of right lower limb to show:
SMALL (SHORT) SAPHENOUS VEIN



Pulses

1. Femoral in groin
2. Popliteal in popliteal fossa
3. Posterior tibial behind media malleolus
4. Dorsalis pedis on dorsum of foot

The small saphenous vein commences at the lateral side of the dorsal venous arch and passes just behind the lateral malleolus. It passes upwards on the posterior aspect of the calf with the sural nerve lying alongside it. It perforates the popliteal fascia and joins the popliteal vein at a variable site