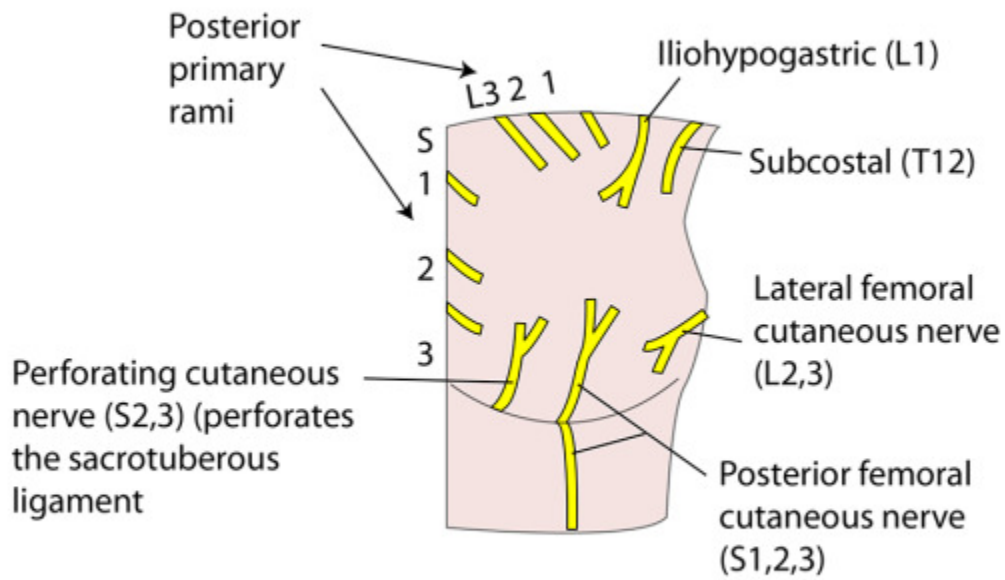
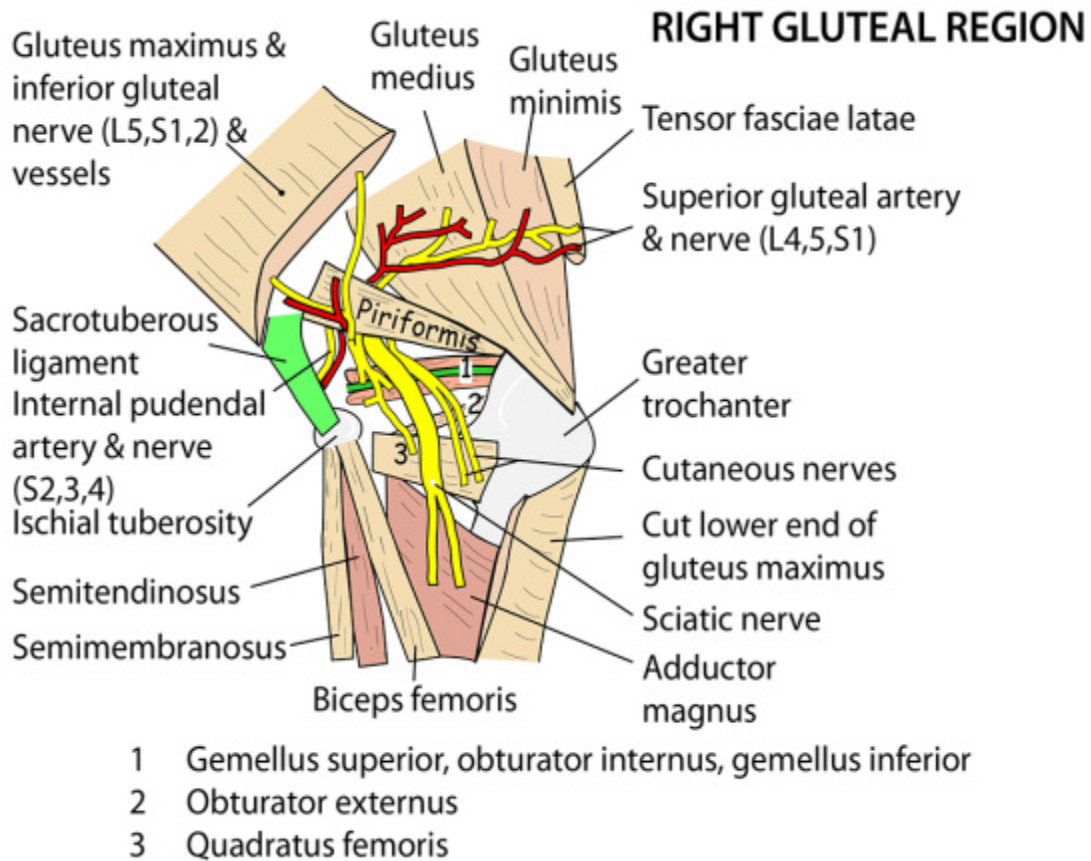


CUTANEOUS NERVE SUPPLY OF BUTTOCKS



NOTE: Pain may be referred between pelvis (autonomics S2,3) and the posterior femoral cutaneous nerve (S2,3)



EASY WAY TO REMEMBER ROOT VALUES OF GLUTEAL MUSCLES

