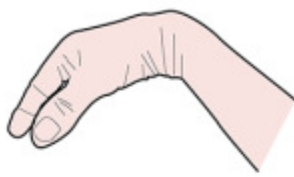
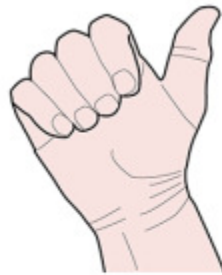
4 CATEGORIES OF ACTION OF THE ANTERIOR FOREARM MUSCLES



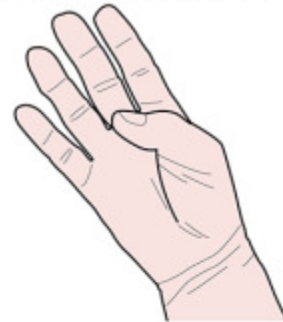WRIST FLEXION

Flexor carpi ulnaris
Flexor carpi radialis



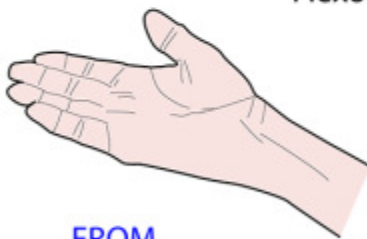FINGER FLEXION

Flexor digitorum superficialis
Flexor digitorum profundus



THUMB FLEXION

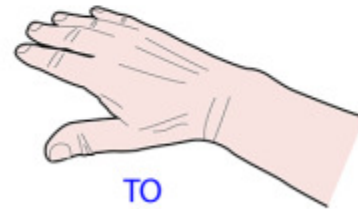
Flexor pollicis longus



**FROM
SUPINATION**



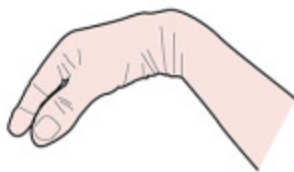Pronator teres
Pronator quadratus



**TO
PRONATION**

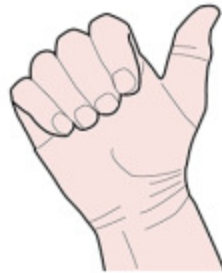All supplied by MEDIAN nerve except FCU & 1/2 FDP - ULNAR nerve

4 CATEGORIES OF ACTION OF THE ANTERIOR FOREARM MUSCLES



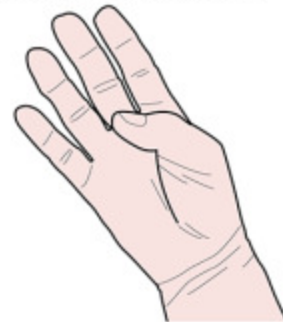WRIST FLEXION

Flexor carpi ulnaris
Flexor carpi radialis



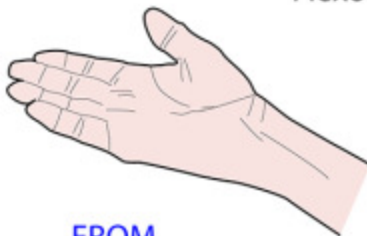FINGER FLEXION

Flexor digitorum superficialis
Flexor digitorum profundus



THUMB FLEXION

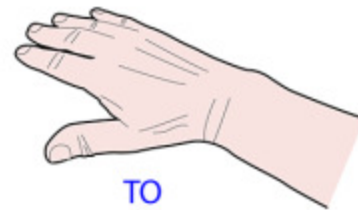Flexor pollicis longus



**FROM
SUPINATION**



Pronator teres
Pronator quadratus



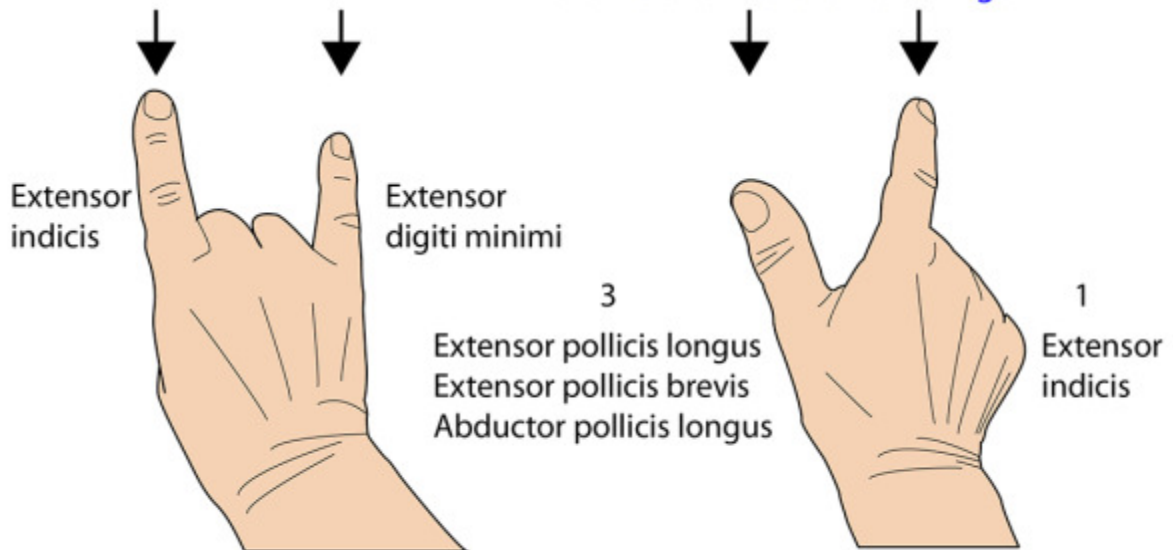
**TO
PRONATION**

All supplied by MEDIAN nerve except FCU & 1/2 FDP - ULNAR nerve

RULES FOR EXTENSOR TENDONS

In addition to tendons of extensor digitorum these **two fingers have an extra tendon** of their own

Four muscles arise deep in the posterior forearm and have tendons that pass to these **two digits in the ratio of 3 to the thumb and 1 to the index finger**



All supplied by **RADIAL** nerve or its posterior interosseous branch

EXTENSOR TENDONS ON DORSUM OF HAND

