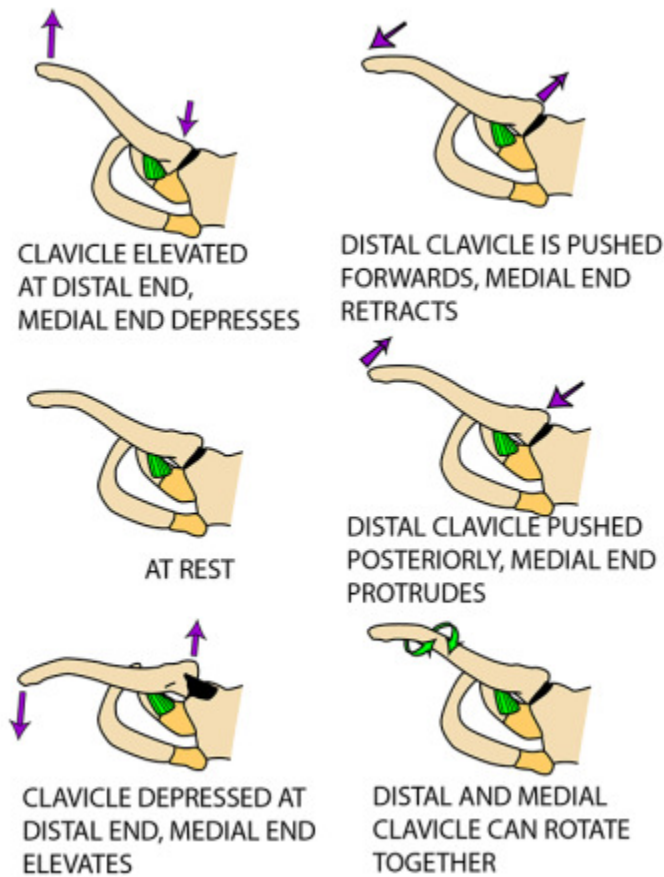


Movements at Sternoclavicular Joint and Abduction of the Shoulder



MOVEMENTS AT THE STERNOCLAVICULAR JOINT

In view of all the movements described here and the ability to pivot on the costoclavicular ligament, the sternoclavicular joint can be regarded as having many of the features of a ball and socket joint

ABDUCTION AT SHOULDER

- External rotation: infraspinatus (suprascapular n)
- Rotation of scapula: Trapezius (spinal XI) Serratus anterior - lower fibres (long thoracic n)
- Mostly deltoid (axillary n) Supraspinatus (suprascapular n)
- Supraspinatus (suprascapular n) & some deltoid (axillary n)

