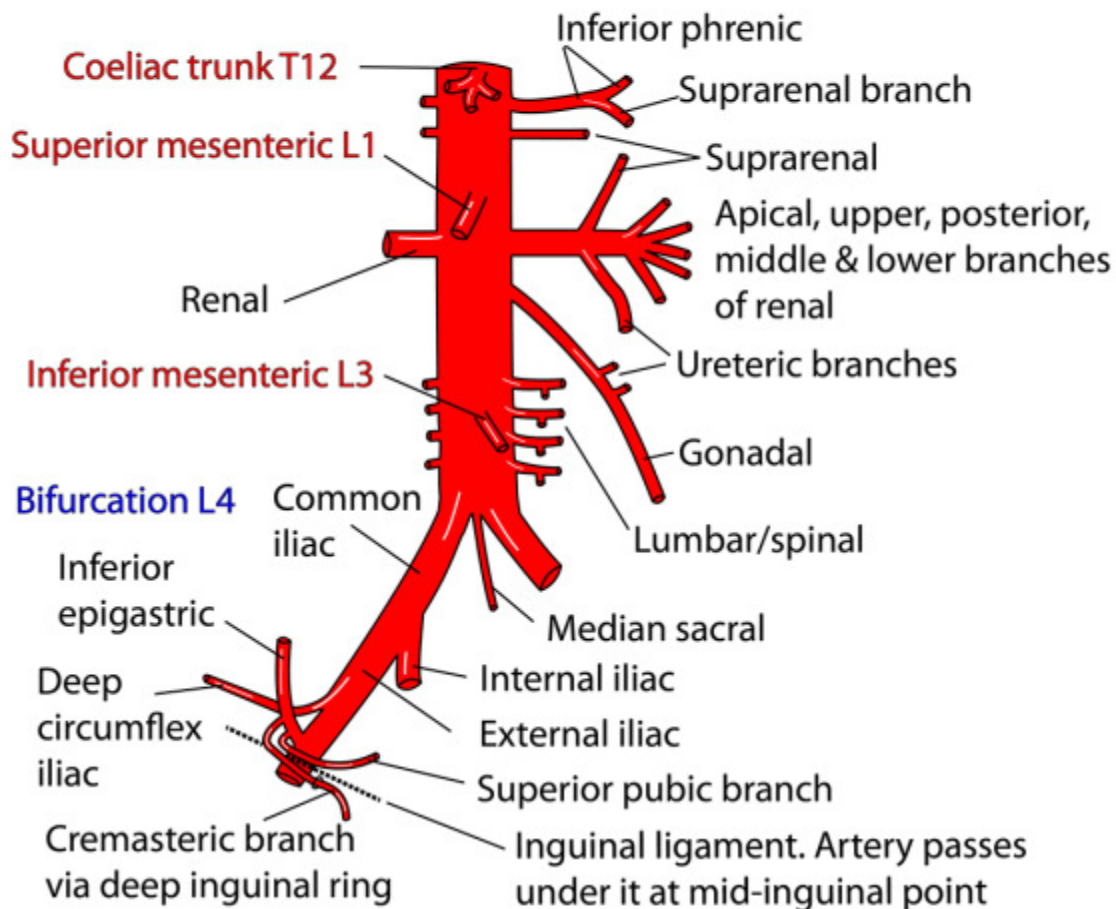


Abdomen: Posterior abdominal wall

ABDOMINAL AORTA AND RIGHT EXTERNAL ILIAC ARTERY



Relations of aorta

Left lateral: Sympathetic chain

Right lateral: IVC, Cisterna chyli

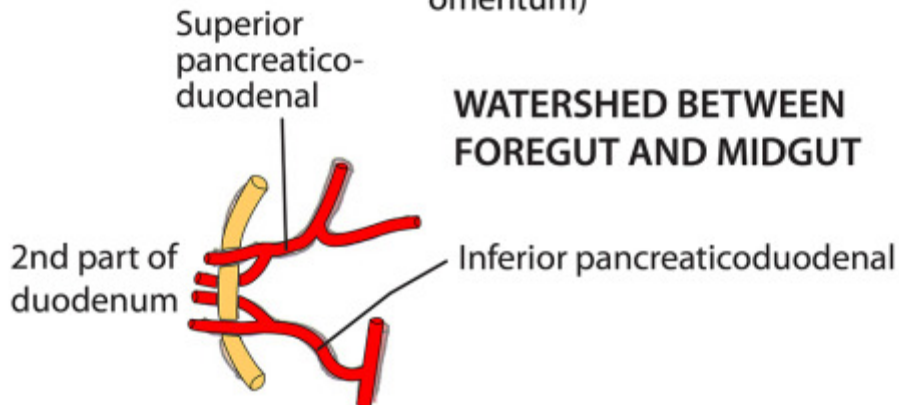
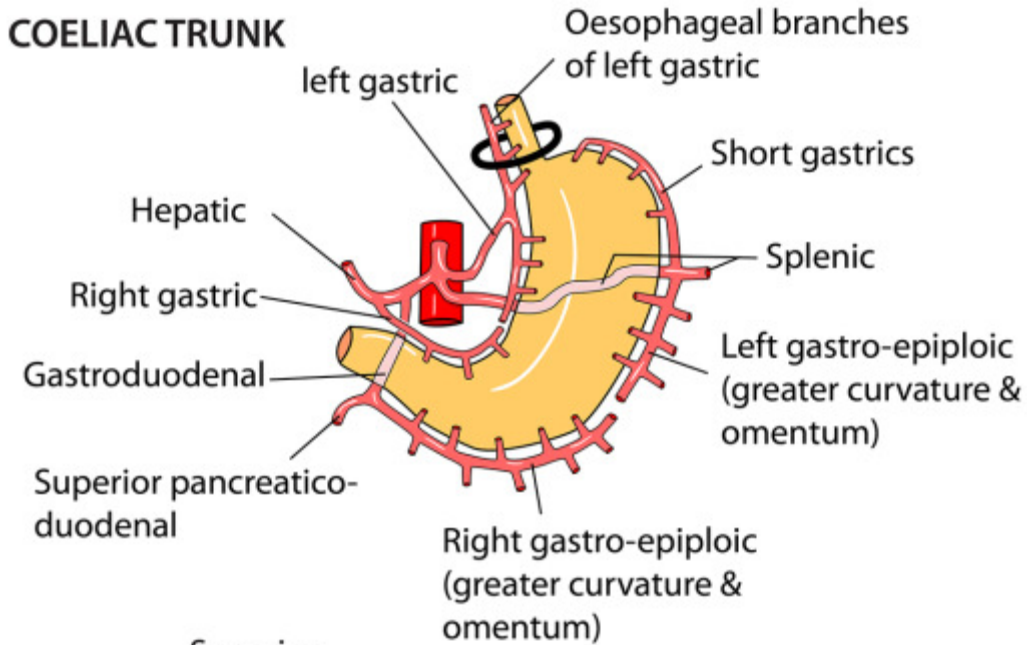
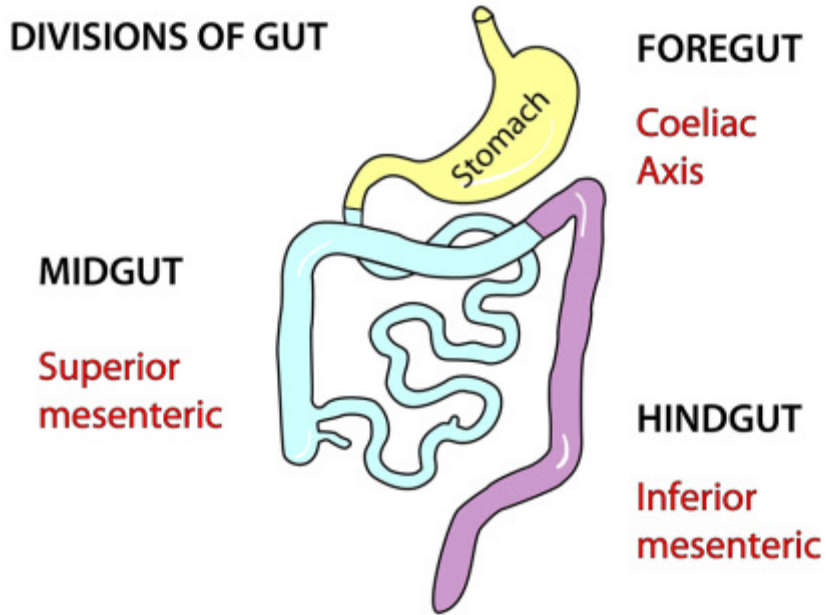
Both lateral: Azygos veins, para-aortic nodes, coeliac ganglia

Anterior: Pancreas, splenic vein, left renal vein, 3rd part duodenum, mesentery, nodes, autonomic plexus, lesser sac, stomach, omentum, small bowel

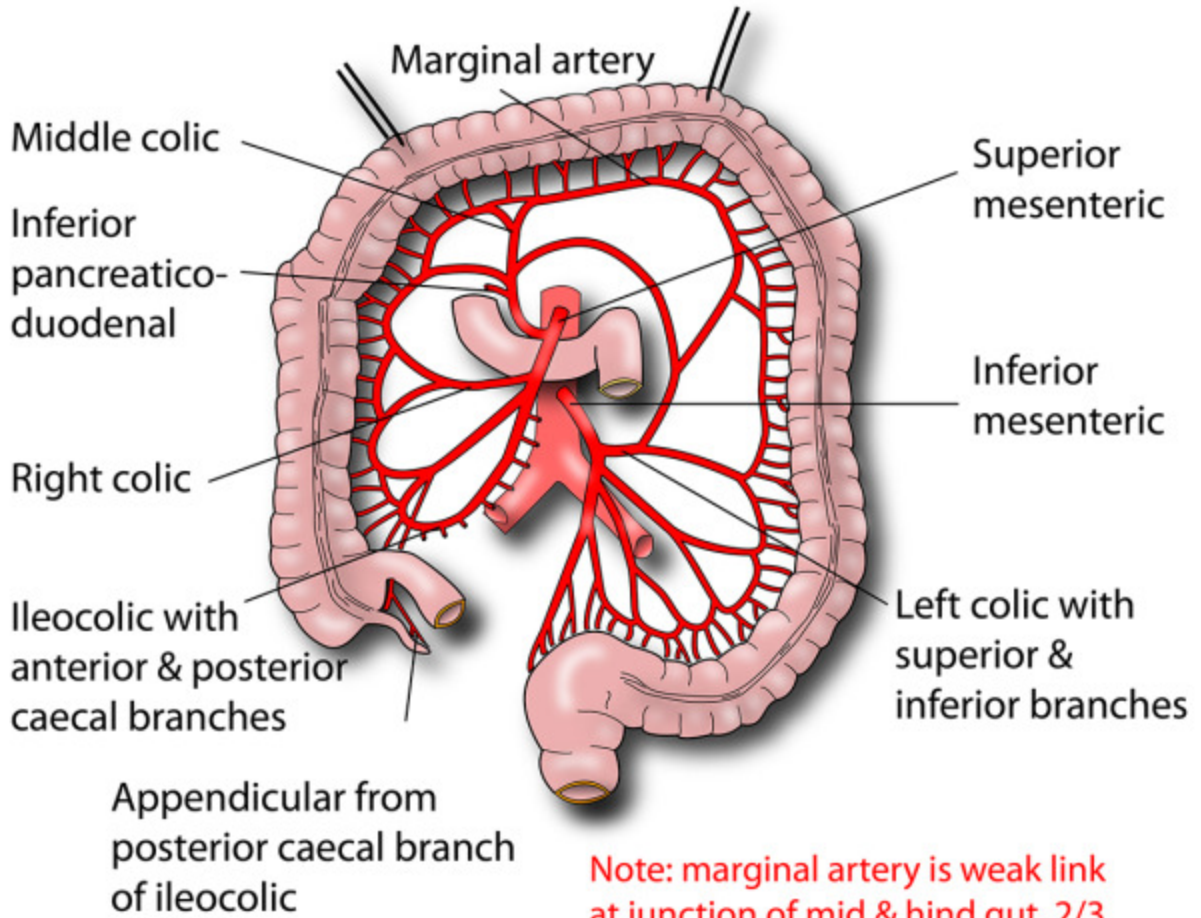
Posterior: T12-L4 vertebrae, left lumbar veins

PRINCIPLES OF BOWEL ARTERIAL SUPPLY

COELIAC TRUNK

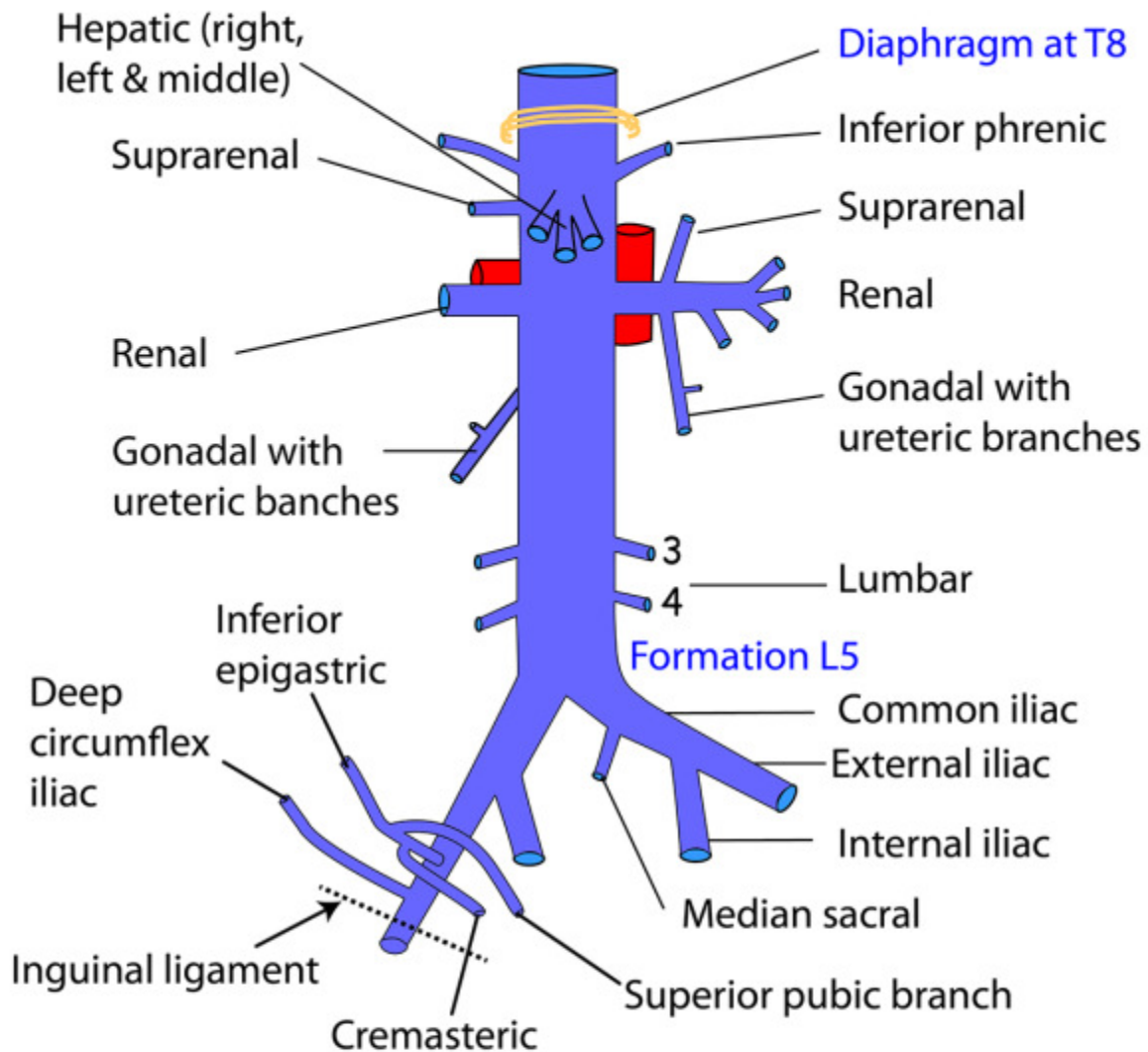


SUPERIOR & INFERIOR MESENTERIC ARTERIES



Note: marginal artery is weak link at junction of mid & hind gut, 2/3 along transverse colon

INFERIOR VENA CAVA



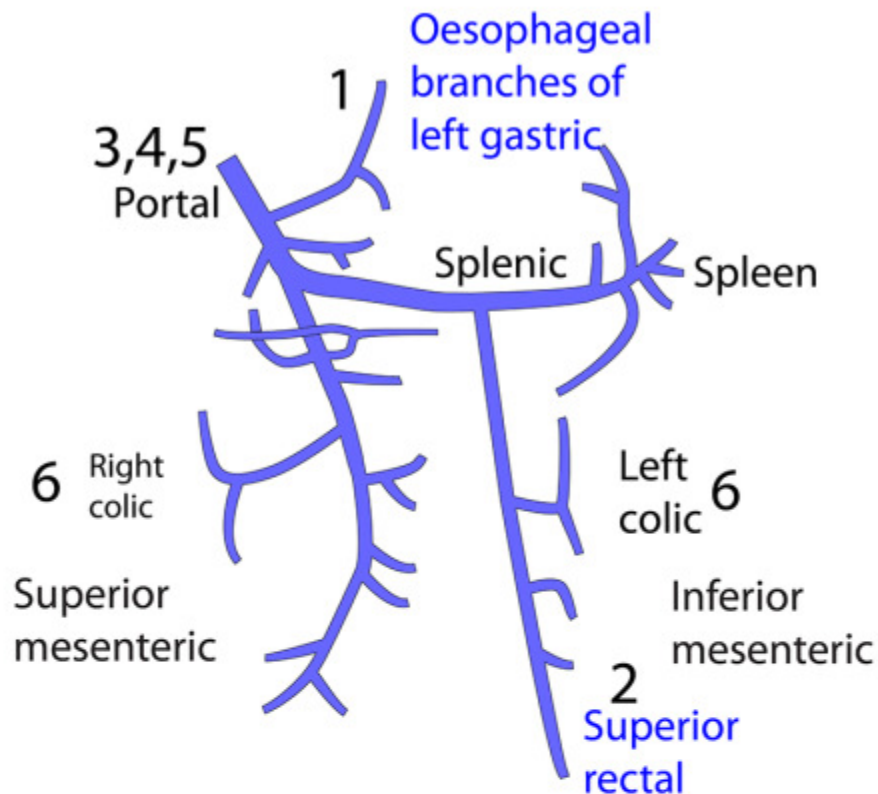
Relations of IVC

Anterior: Bile duct, liver, opening of lesser sac, 1st/3rd parts of duodenum, head of pancreas, small bowel, right common iliac artery, root of mesentery, right gonadal artery, portal vein

Posterior: Right renal artery, lumbar arteries, right crus of diaphragm, right suprarenal & its artery, bodies of L3,4,5 vertebrae, right psoas, right sympathetic chain, right coeliac ganglion

Note: NO tributaries from gut

PORTOSYSTEMIC ANASTOMOSES



1 Lower oesophagus

Portal: Oesophageal branches of left gastric veins
Systemic: Azygos veins

4 Bare area of liver

Portal: Hepatic/portal veins
Systemic: Inferior phrenic veins

2 Upper anal canal

Portal: Superior rectal vein
Systemic: Middle/inferior rectal veins

5 Patent ductus venosus (rare)

Portal: Left branch of portal vein
Systemic: Inferior vena cava

3 Umbilical

Portal: Veins of ligamentum teres
Systemic: Superior/inferior epigastric veins

6 Retroperitoneal

Portal: Colonic veins
Systemic: Body wall veins

LUMBAR PLEXUS

L1,2,3,4,5

