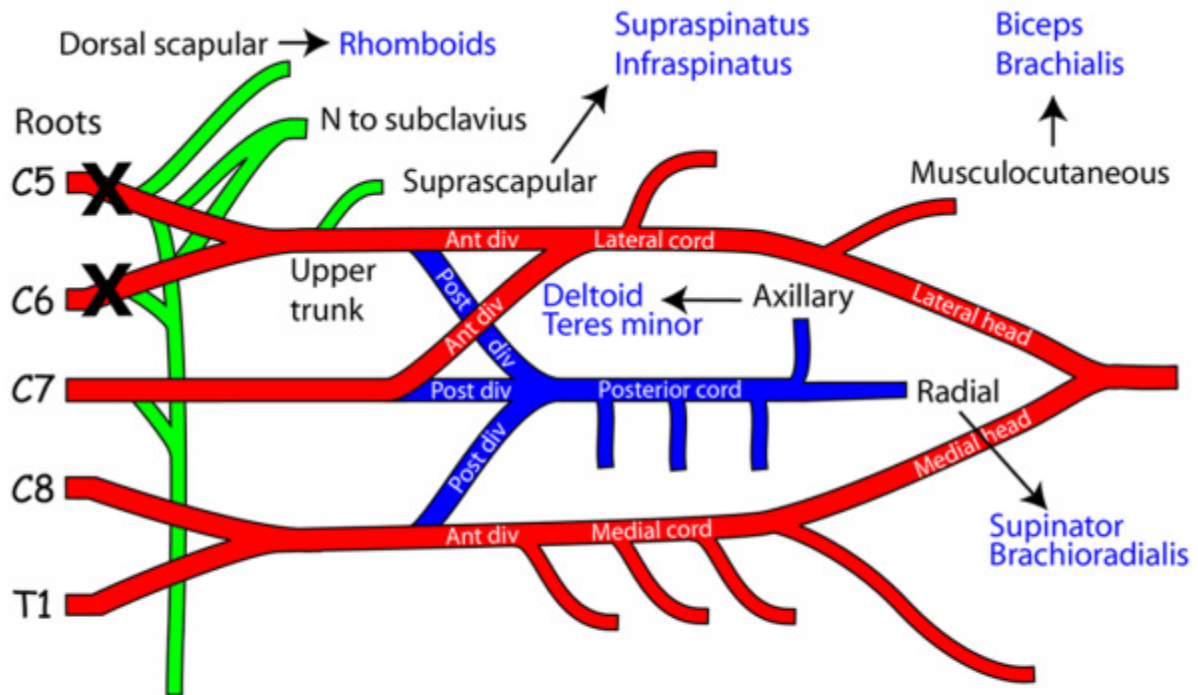


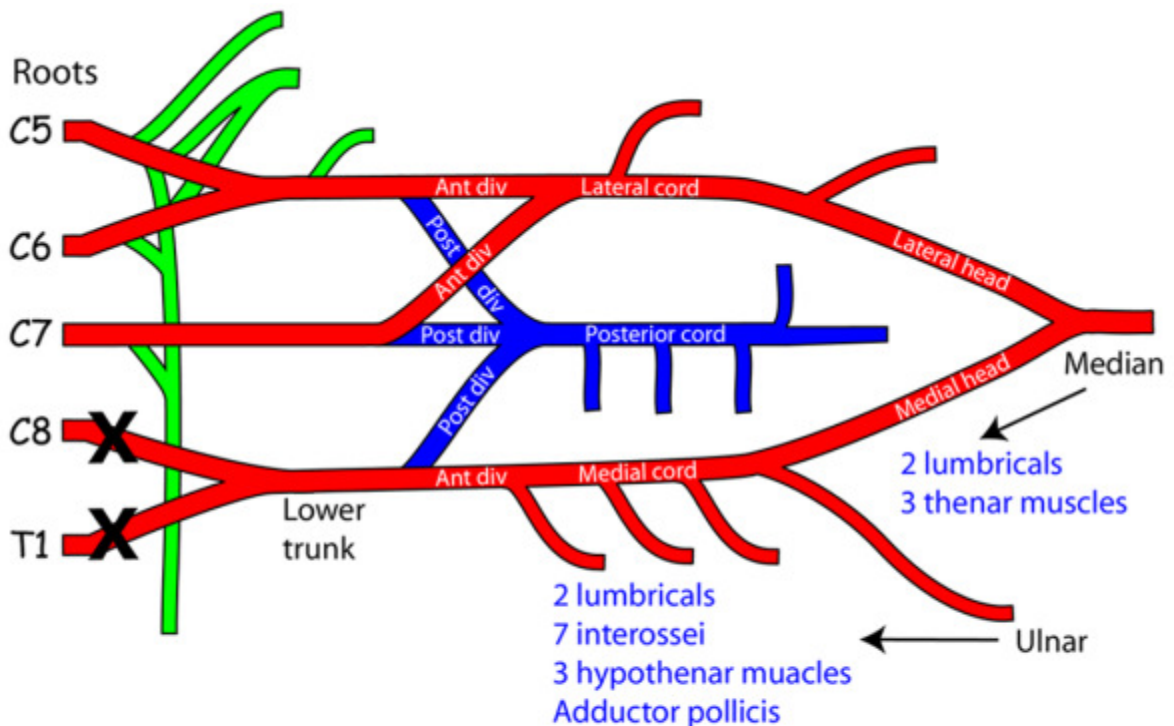
Brachial Plexus part 2



**LESIONS OF THE UPPER ROOTS OF THE BRACHIAL PLEXUS**

Only shown are the muscles that will be severely affected.

Domination: latissimus dorsi, pronator teres & both pectoral muscles



**LESIONS OF THE LOWER ROOTS OF THE BRACHIAL PLEXUS**

Only shown are the muscles that will be severely affected.

Domination: long extensors on MP joints & long flexors on IP joints